

## AN ELDERLY SMOKER WITH ABNORMAL CHEST FILM

M Rohsila<sup>1</sup>, Nani D<sup>2</sup>

<sup>1</sup>Department of Radiology, School of Medical Sciences, Universiti Sains Malaysia, Kubang Kerian, Kelantan. (Rohsila Muhamad)

<sup>2</sup>Department of Family Medicine, School of Medical Sciences, Universiti Sains Malaysia, Kubang Kerian, Kelantan. (Nani Draman)

**Address for correspondence:** Dr Rohsila Muhamad, Department of Radiology, School of Medical Sciences, Universiti Sains Malaysia, Kubang Kerian, Kelantan, Malaysia. Tel: 609-767 3000/6619, Fax: 609-767 6611, Email: mrohsila@yahoo.com

Rohsila M, Nani D. An elderly smoker with abnormal chest film. *Malaysian Family Physician*. 2011;6(2&3):89-90

### CASE HISTORY

A 70-year-old ex-smoker presented with history of fever, cough, right sided chest pain associated with loss of weight and loss of appetite for four months. He had a few episodes of chest infection which was treated by general practitioners. There was no other medical illness before. Work-up for tuberculosis was negative.

On examination, he was comfortable but cachexic. There was no cervical lymphadenopathy. There was decrease in air entry at the right upper zone. His chest X-ray is shown in Figure 1.

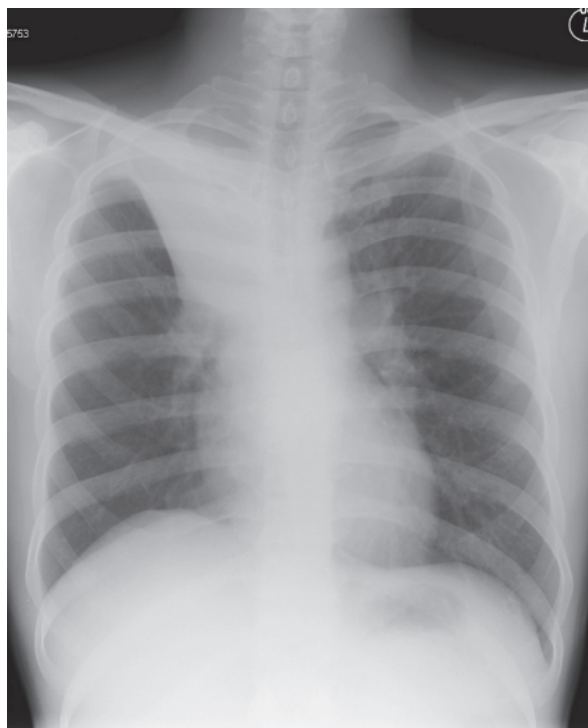


Figure 1

### QUESTION:

1. Describe the chest X-ray finding?
2. What are the differential diagnoses?
3. What is the most likely diagnosis?

### ANSWER:

1. There is homogenous opacity in the right upper zone with a well defined inferior border extending towards the right hilum. The mediastinum is widened with prominent lobulation at the right hilar region. No pleural effusion bilaterally. No associated cavitation or calcification seen.

These findings are in keeping with right upper lobe collapse either due to right upper lobe bronchus obstruction or total external compression. The inferior border of the opacity is due to the elevated horizontal fissure.

When the right upper lobe bronchus is obstructed or compressed, the segmental and sub-segmental branches of the right upper lobe bronchus are not aerated and the distal alveolar gas will be reabsorbed. Therefore, there is no air bronchogram (air in the bronchial tree) seen.

Right upper lobe lies anterior to the oblique fissure and bordered inferiorly by the horizontal fissure. When there is volume loss, both lung fissures will move superomedially towards the mediastinum and the right hilum will be elevated. Compensatory hyperexpansion of the middle and right lower lobe will cause further concavity of the horizontal fissure.<sup>1</sup>

2. Bronchial obstruction may be secondary to a foreign body, benign or malignant tumor, mucus plug, blood clot and as well as bronchial transection, fibrotic stenosis from granulomas or inflammation.

Bronchogenic carcinoma can cause endoluminal lesion obstructing the right upper lobe bronchus.<sup>2</sup> Endobronchial tuberculosis can cause bronchial stenosis and further obstruction by mucous secretion or granuloma nodule. Pulmonary tuberculosis (PTB) occurs at the peripheral lung rather than centrally to cause significant upper lobe collapse unless when complicated with fibrosis. PTB will have lung parenchymal consolidation with cavitation or calcification. A large foreign body inhalation, if sited at the right upper lobe bronchus, will cause upper lobe collapse.

Central or proximal bronchial compression by mediastinal mass or large hilar mass can cause upper lobe collapse.<sup>2,3</sup> Differential diagnosis of mediastinal mass includes thymoma, teratoma, lymphoma or enlarged thyroid gland.

3. The most likely diagnosis in this case is large mediastinal mass causing compression to the right upper lobe bronchus leading to right upper lobe collapse. CT scan of this patient revealed a large lobulated mediastinal mass. CT guided biopsy of the mediastinal mass showed moderately differentiated adenocarcinoma (possibly a secondary from the lung). The patient was subsequently referred to the oncology team.

## REFERENCES

1. Gupta P. The Golden S sign. *Radiology*. 2004;233(3):790-1.
2. Woodring JH. Determining the cause of pulmonary atelectasis: a comparison of plain radiography and CT. *AJR Am J Roentgenol*. 1988;150(4):757-63.
3. John RE, Narang VP. A boy with an anterior mediastinal mass. *Anaesthesia*. 1988;43(10):864-6.